

Back to Reality: Infrared Thermography (IRT) as an Objectifier of Equine Back Pain and Saddle-fitting Problems

Joanna L. Robson, President, DVM, CVSMT, CMP, CVA, SFT, CIT

Inspiritus Equine, Inc.
8 Golden Gate Circle
Napa, CA 94558
Ph: 707-738-7110

www.InspiritusEquine.com
Email: jrobsondvm@inspiritusequine.com

Abstract

Infrared Thermography (IRT) has many uses in the equine industry. In biological systems the detection of surface heat is directly correlated with changes in circulation, thus providing evidence of inflammation or decreased perfusion. Currently, the diagnosis of equine back pain is subjective, reliant on the veterinarian's ability to palpate using his or her hands, and on the trainer's or rider's knowledge of how training and behavioral problems may relate to equine back pathology and saddle-fitting problems. Modalities such as radiographs or ultrasound provide anatomic evidence of pathologic changes, but require specialized machines, are limited by location, and are not generally feasible in-field for spinal evaluation. Thermal imaging provides a safe, quick, objective image of equine back inflammation, and is a useful tool in proper saddle-fitting. The use of IRT in the equine industry provides objective evidence of equine pain that can help the human handlers to better understand their horses and subsequently effect positive changes that promote maximum equine performance and longevity.

Discussion

Infrared Thermography (IRt) is growing as a diagnostic modality in the equine industry as veterinarians, farriers, trainers, and owners recognize the inherent advantages of thermal imaging. IRt provides a safe, quick, whole-horse evaluation that is simply not possible with any other diagnostic modality currently available in equine medicine. IRt has many uses within the field, including pre-purchase evaluations, localizing mystery lamenesses, monitoring healing, preventing injury, providing baselines, aiding farriers and trimmers, and assessing saddle-fit and rider position.

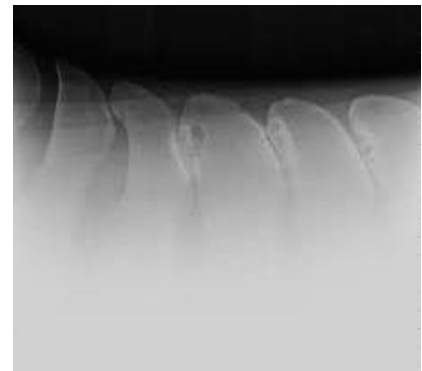
Equine back pain may be one of the most under-detected causes of equine lameness and diminished performance. Equine back pain may manifest as a number of different



Hollow, dropped back. Out behind.

symptoms, including behavioral, training, and conformational problems. Bucking, rearing, tripping, head-tossing, problems with leads, reluctance to go forward, sourness and biting, lumps and bumps on the back, high-spine, and dropped or hollow backs, are just a few of the signs of back pain or pathology. In some cases, these horses are deemed ‘dangerous’ or ‘unable to perform’ while in reality they are suffering from physical pain that can, in many cases, be easily treated by removing the underlying cause –

ill-fitting equipment or imbalanced riders. Many cases of equine back pain are made based on rule-outs; everything else is treated first, and the back is the last body part on the list. Once a diagnosis of back pain is made from a patient history or palpation, or through systematic rule-outs, western medicine may employ localized blocks, radiographs, nuclear scintigraphy, or ultrasound to further highlight an anatomic problem. Often, no diagnostic test is performed, and the patient is merely injected with palliative steroids or other agents that treat the pain as a band-aid, but leave the patient to continue to suffer the causative problem.



Radiograph of “Kissing Spine”

Diseases of the equine back may range from mild muscle soreness, to significant spinal arthritis, ligamentous tears, or extruded disks. Over-riding spinous processes (often called “kissing spine”), chiropractic lesions, and nerve damage are also omnipresent. IRt plays a significant role in detecting back inflammation that may be associated with these listed conditions, and in helping with saddle-fitting. Many clients are unaware of their horse’s back problems until seeing the objective evidence in the images.



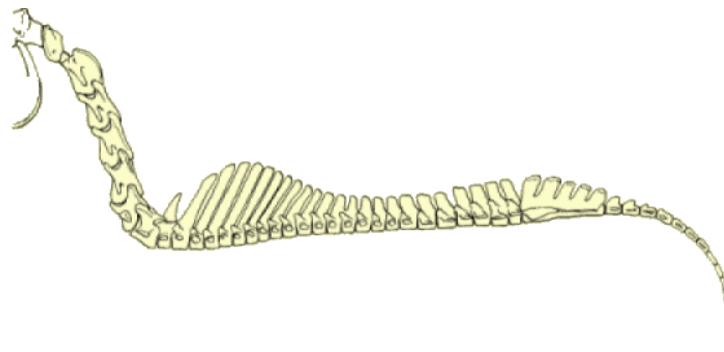
Ears pinned, biting when saddled – signs of equine back pain.

A correctly fitting saddle is one of the most important components of equine health and performance, and is sadly under-recognized as a contributing factor to equine pain and decreased function. The equine anatomy that dictates how and why a saddle must fit correctly is not common knowledge, and trainers and riders more quickly jump to the saddles that are comfortable for themselves, or which are the latest must-have trend in the show arena. The horses, expressing themselves in their only known language, may present with lameness, bucking or rearing under saddle, decreased run times, conformational changes, biting and kicking when saddled, or behavioral anxiety and stomach ulcers.

Instead of recognizing these symptoms for what they represent – a horse in pain – human ignorance results in these horses being subjected to harsh training equipment and methods to force a desired physical or mental result.

IRt provides objective evidence of the changes in these horses' backs and musculature, and can show before and after saddle-fitting patterns of pressure and balance that help to educate the trainers and riders. Therefore, IRt provides a new voice for the horses; thermal imaging is not just a tool, but an additional step in maintaining the ethics and morals of equine sport and health.

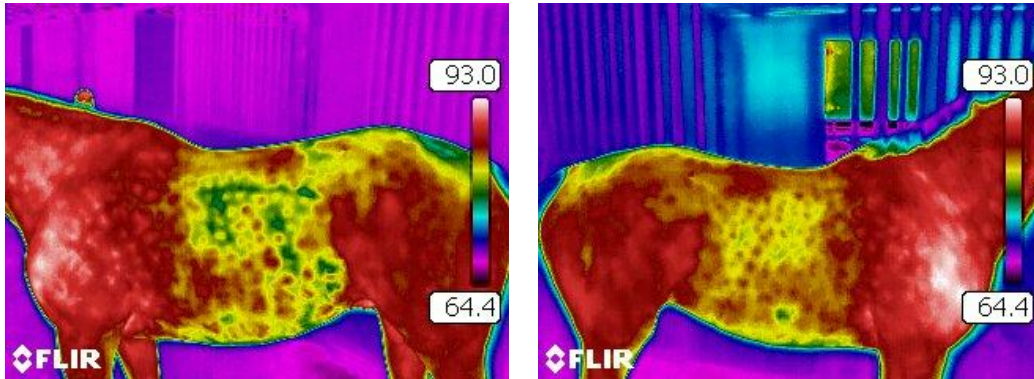
The equine spine is comprised of 7 cervical vertebrae, 18 thoracics, 6 lumbar, and 5 fused sacral bones. The tail is typically 18-20 smaller connected bones, similar to the bones in the human digit. These bones are connected through a ligamentous and muscular bridge. The nuchal ligament, a thick fibrous band, extends from the back of the skull to the withers, and then continues as the dorsal spinous ligament to the tail. When the horse moves in harmony, this suspension bridge allows the bones, joints, and soft-tissues to move fluidly, absorbing shock and dissipating forces. When pain or pressure occurs over the nerves, bones, or muscles, this bridge fails and collapses, causing strain and inflammation of soft-tissues and joints. Over even short periods of time, permanent damage may ensue, shortening or ending equine athletic careers.



The Equine Skeletal Formula: C7-T18-L6-S5-Cd20

Let's examine specific case examples.

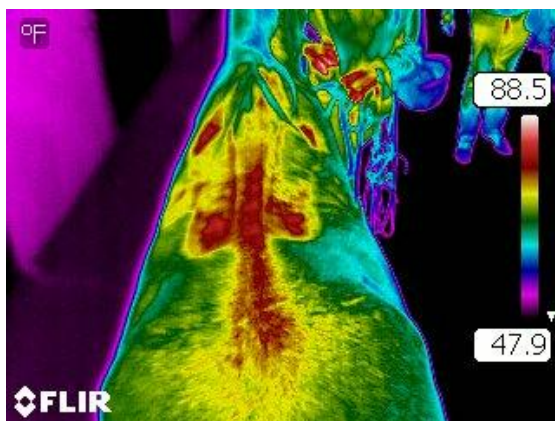
Case One: Eight year-old European Warmblood gelding with behavioral issues, lead-swapping, and problems with jumping. His owner had his saddle fitted twice by a “saddle-fitter” who assured her that the saddle was not the horse’s problem. He continued to have issues, and was imaged to participate in an un-related thermography study. Thermal images showed significant inflammation in the horse’s back, with an apparent saddle-outline through the shoulders and loins. The owner reported that she had not ridden her horse for 3 days prior to his being scanned.



Left and right lateral views showing heat in the loins and a panel outline consistent with bridging. Behavioral issues prevented “over the back” imaging.

Outcome: Based on these images, the horse’s owner sold her current saddle and quickly sought a correctly fitting saddle. The horse had appropriate rest and therapy for 30 days, and returned successfully to jumping and competing. Follow-up images confirmed the completed resolution of focal heat in the back.

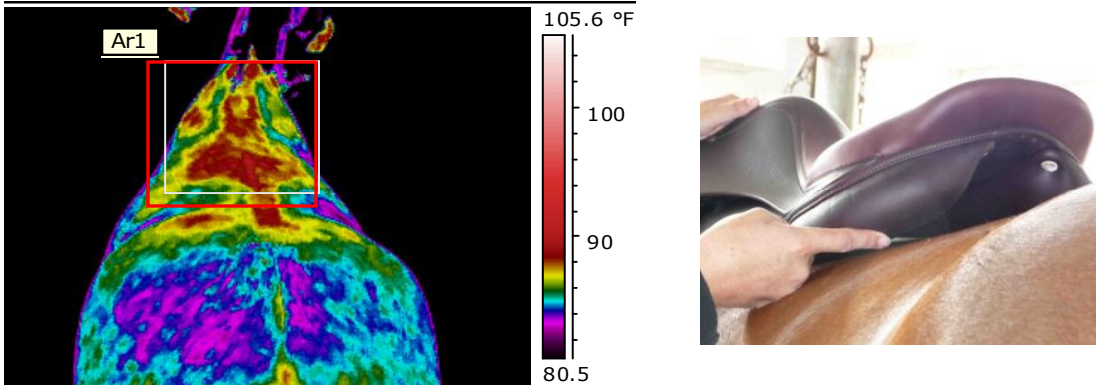
Case Two: Sixteen year-old swayback Quarterhorse used in a therapeutic riding program. His saddle is always shifting, and the group is worried that his back may be injured by the saddle.



Dorsal view showing a distinct bridging pattern created by a bridging saddle – there is focal pressure at the front and rear of the panels, with no contact in between.

Outcome: Based on the images and a gross saddle evaluation, the saddle was determined to be bridging and putting uneven pressure on the horse’s back. A different saddle was selected with improved fit, and a pad to equalize the swayback was utilized.


Case Three: International level Hunter gelding with a tight back and diminished performance. Palpation over the withers and low back would cause the horse to drop down in pain. The saddle was an older saddle in the barn being used while a new saddle was being made. The owner had concerns that saddle-fit was an issue, and had been in an argument with the trainer on this point.



Dorsal view of the patient showing asymmetrical pressure from the saddle on the horse's back. There is increased pressure over the left shoulder and shoulder-hole, withers, and left paraspinal muscles. This indicated a saddle that was shifting or falling, too tight through the tree and channel, and could represent a rider sitting heavier on one side.

Outcome: Based on image evidence, the owner elected not to ride the horse until her new saddle was delivered. The new saddle was also determined to be an improper fit. The owner and trainer conflict escalated, and the owner elected to move to a new barn.

Case Four: Saddle too narrow and bridging on the left side. Leather saddles will show a nice mirror pattern to the horse's back when the procedure is carried out correctly. Synthetic saddles are harder to evaluate, but are still imaged as part of a saddle-fitting evaluation.



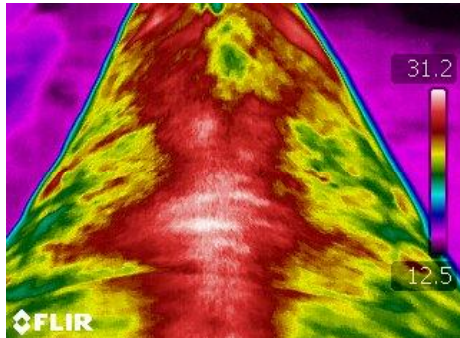
The underside of the saddle upon removal from the horse's back. Note the red pressure points at the front of the tree, and the interrupted pattern through the left panel. The picture at right shows the common site of pinching over the horse's shoulders from a saddle tree that is too narrow.

Outcome: This saddle is too narrow through the tree and is pinching the horse's withers and shoulders. Because it sits too high on the horse, there is uneven contact through the panels. There is more pressure along the right panel and flap, and the left panel shows a bridging pattern.

In evaluating thermal images for equine back inflammation, one must remember that thermography is a physiologic modality only and is not anatomically specific. Radiographs or ultrasound are often needed as a follow-up to back scans in order to provide a complete diagnosis and treatment.

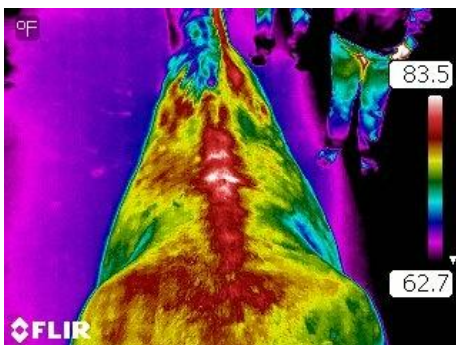
Examples of back pathology (confirmed with anatomic imaging by rDVM):

Case One: Generalized Inflammation and Over-riding Spinous Processes in the Low Thoracics



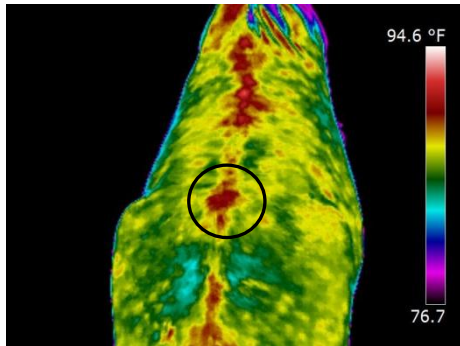
The red region correlates to paraspinal muscle inflammation, with white focal heat over spinal arthritis caused by “kissing spines”.

Case Two: Over-riding Spinous Processes



Heat in the dorsal midline can be typical, but the focal white spots and radiating red are classic thermal patterning for Kissing Spines. The diagnosis, however, must always be confirmed with anatomical imaging.

Case Three: Chiropractic Lesions – Vertebral Rotations and Posterior Sacrum



Focal hotspots over the dorsal spinous processes clearly outline a misaligned spine with associated inflammation.

Conclusion

In summary, infrared thermography has many varied uses in the equine industry. Two specific examples of its success are detecting back inflammation and saddle-fitting problems. The objective image of heat and pressure-points has a positive impact on client understanding, and may improve the veterinarian's localization and diagnosis of the lesions, subsequently followed by improved treatment and therapy options. The saddle industry is largely motivated by sales and sponsorship, with the horse's best interests often in second place to rider comfort. Objectifying the inflammation and pathology created by ill-fitting tack and imbalanced riders will encourage industry-wide changes for the welfare of the horse.

Joanna Robson, DVM, CVSMT, CMP, CVA, SFT, CIT is owner of Inspiritus Equine, Inc. in Napa, CA and is the Veterinary Technical Director for EquineIR. Her practice is dedicated to finding and treating the underlying causes of decreased performance, and she works with other world-class leaders in the equine industry to provide an integrated, whole-horse approach to health and wellness. www.InspiritusEquine.com